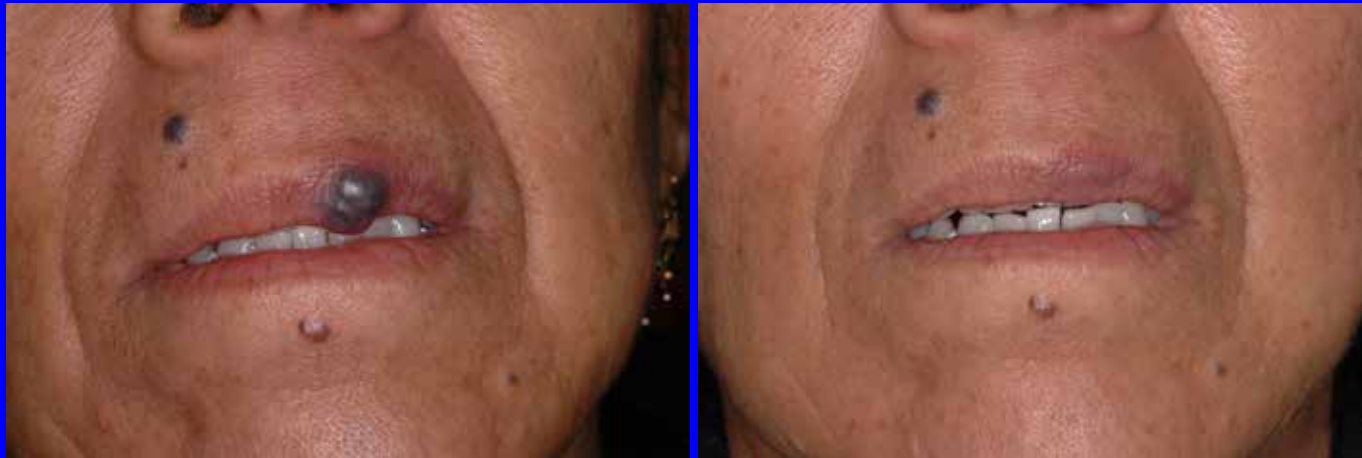
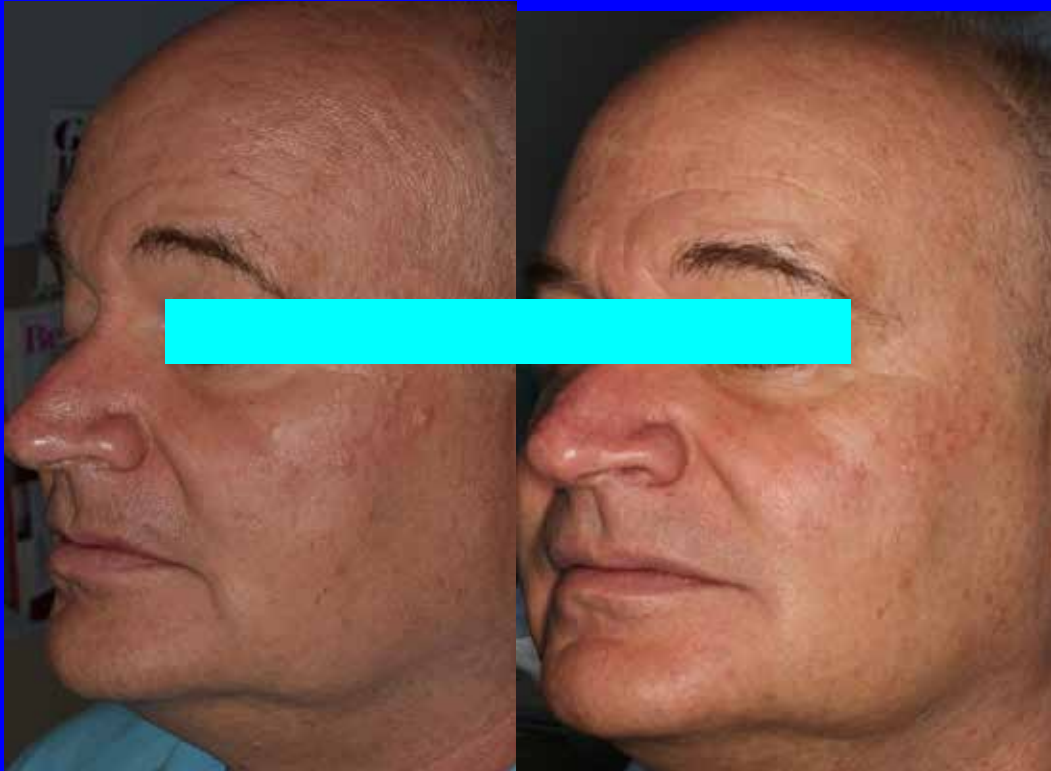
Maui Derm 2021 Good cases

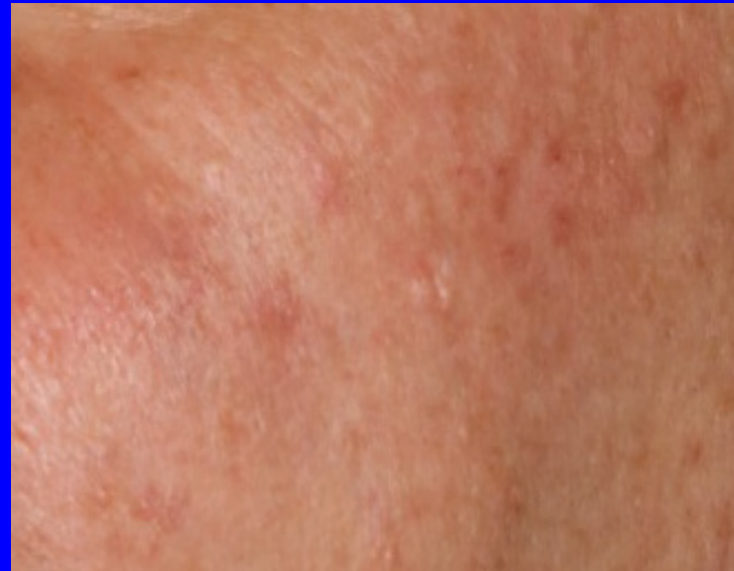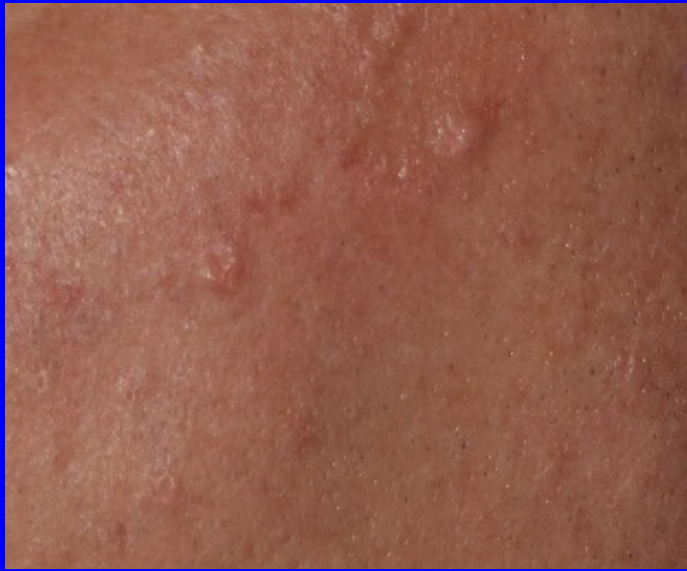E. Victor Ross MD

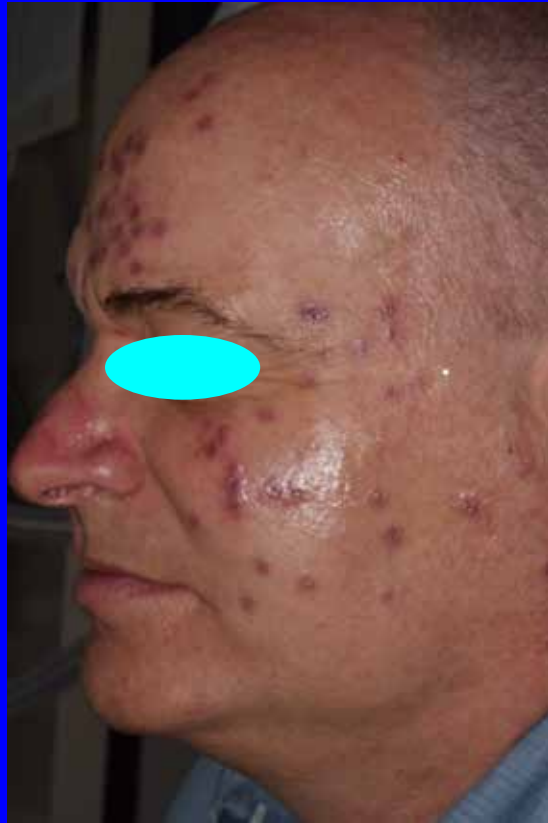Venous lake, pre post treatment



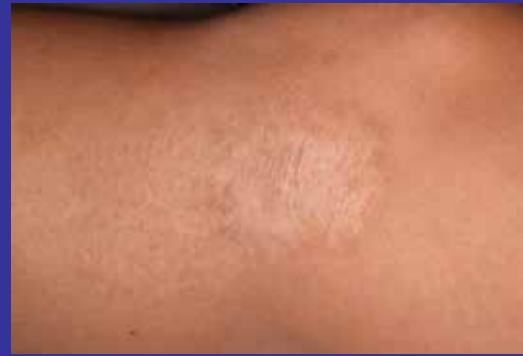
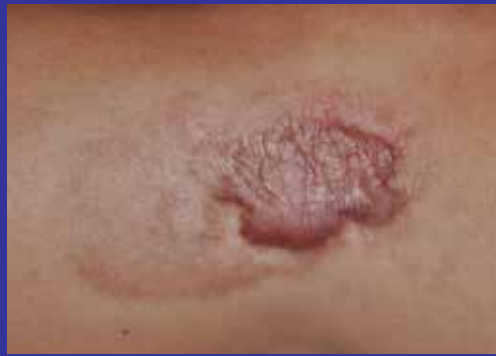
Sebaceous hyperplasia before and after

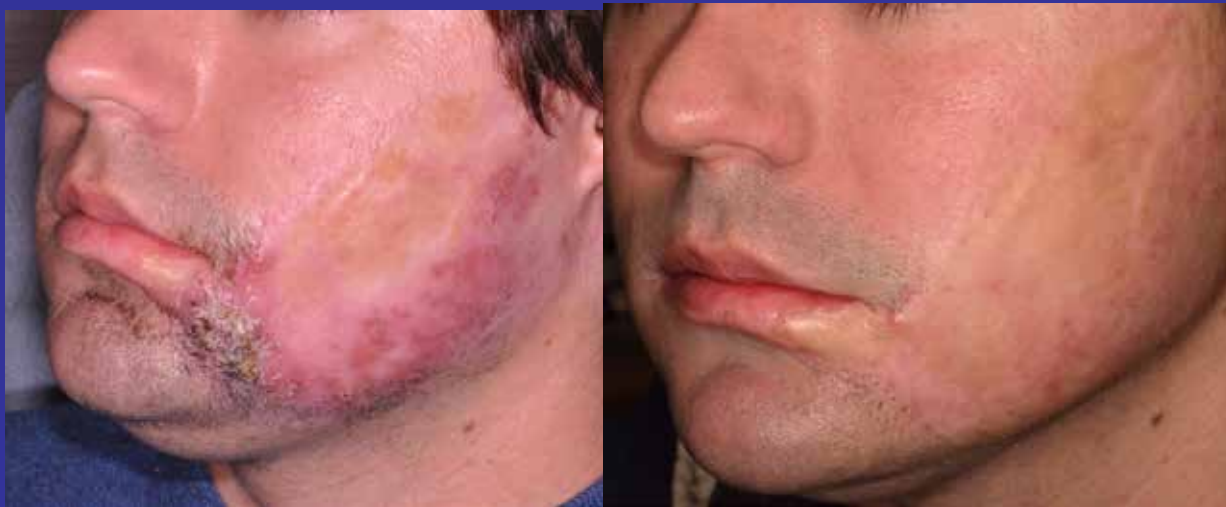



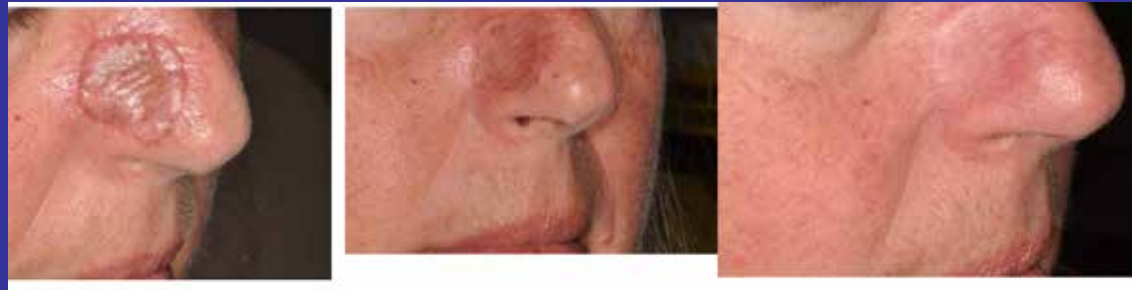scar after 10 txs



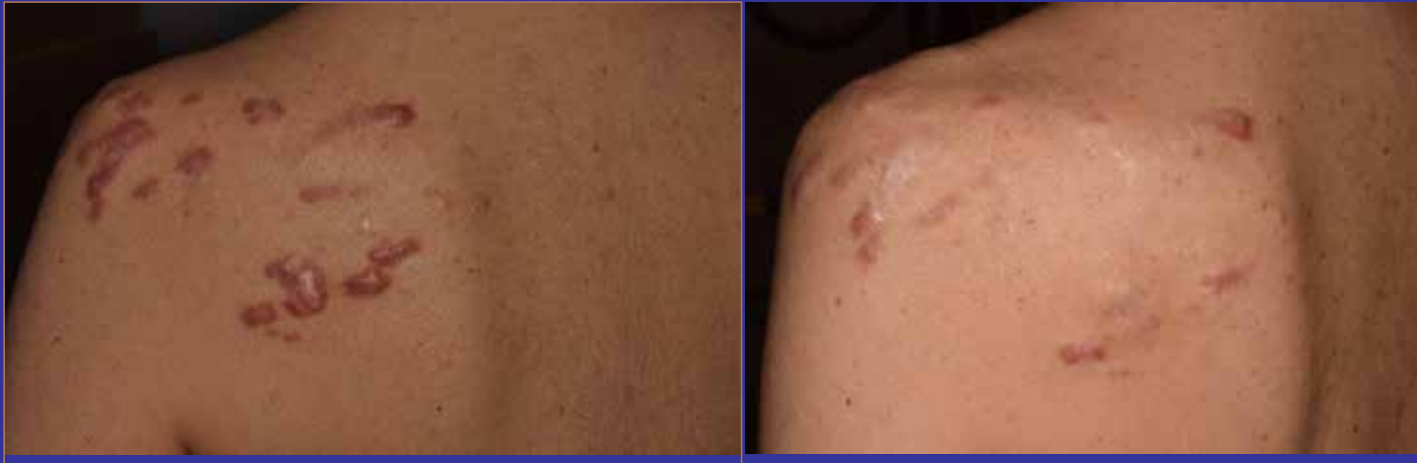scar left cheek icon 1540 nm



Mohs scar erbium

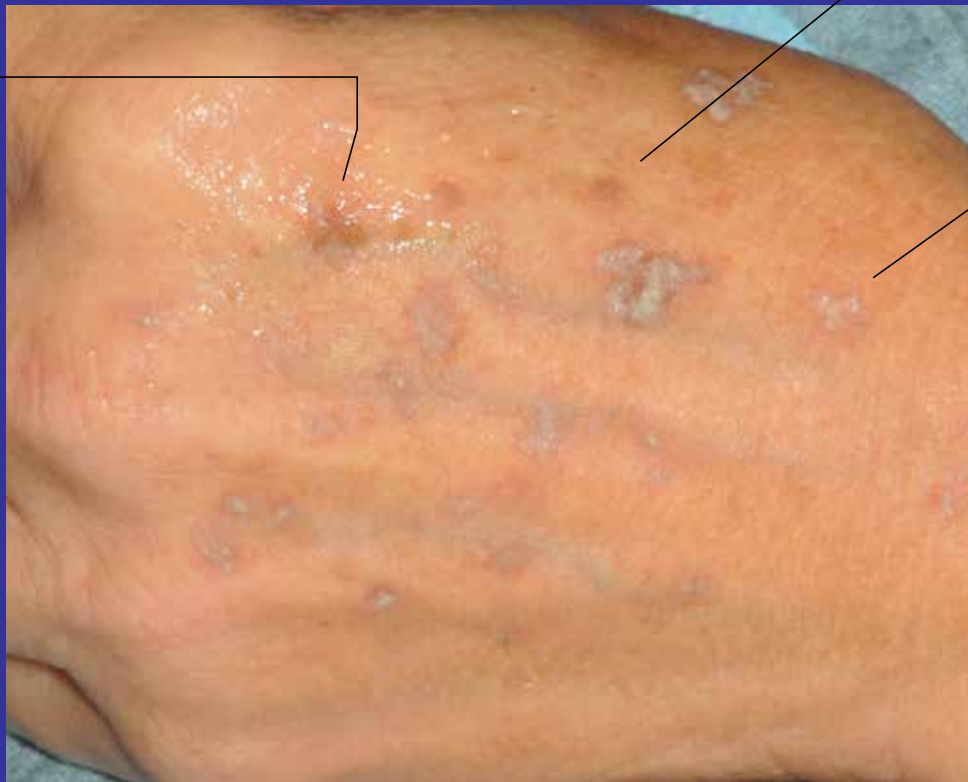

scar back



Endpoints pigment

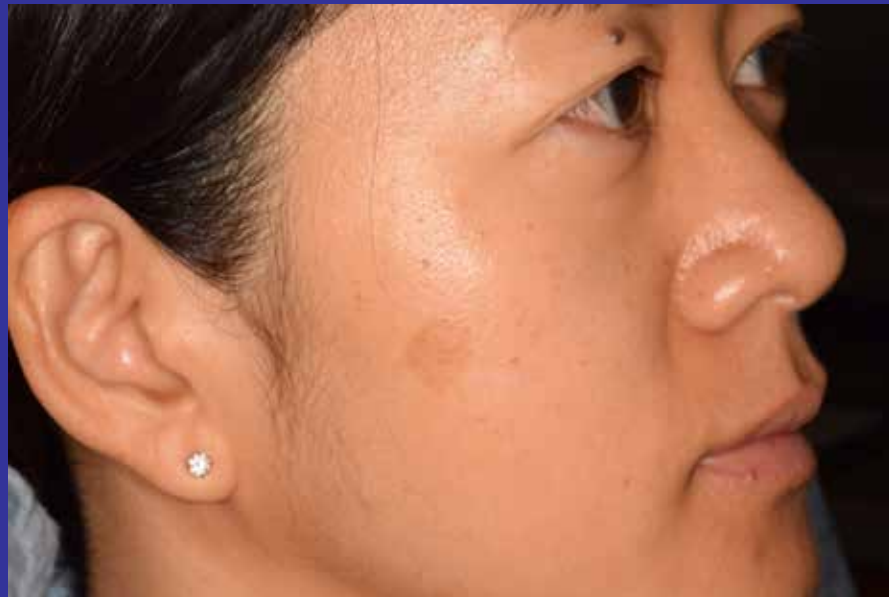Just post q
alex plus
gel- note
looks almost
same as
long pulse



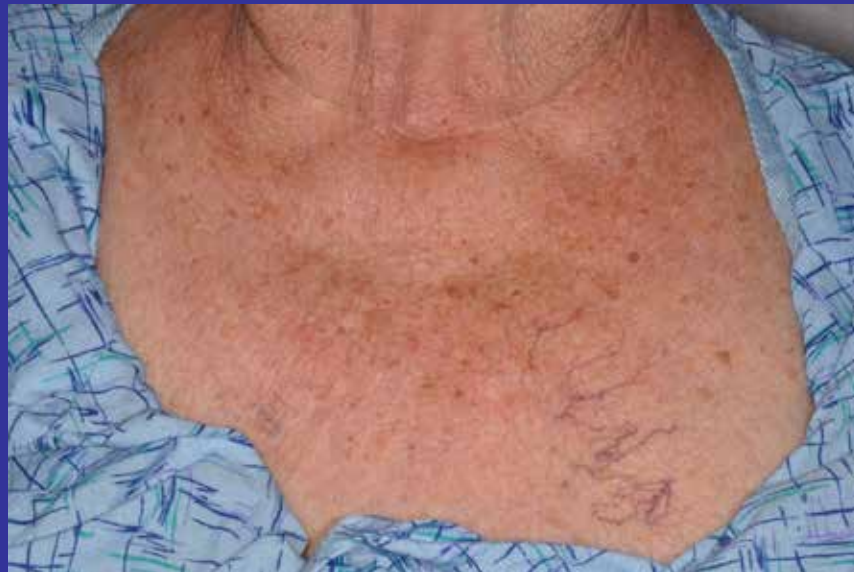Just post
4 mm max
g 40-10ms

Typical
just post q
alex

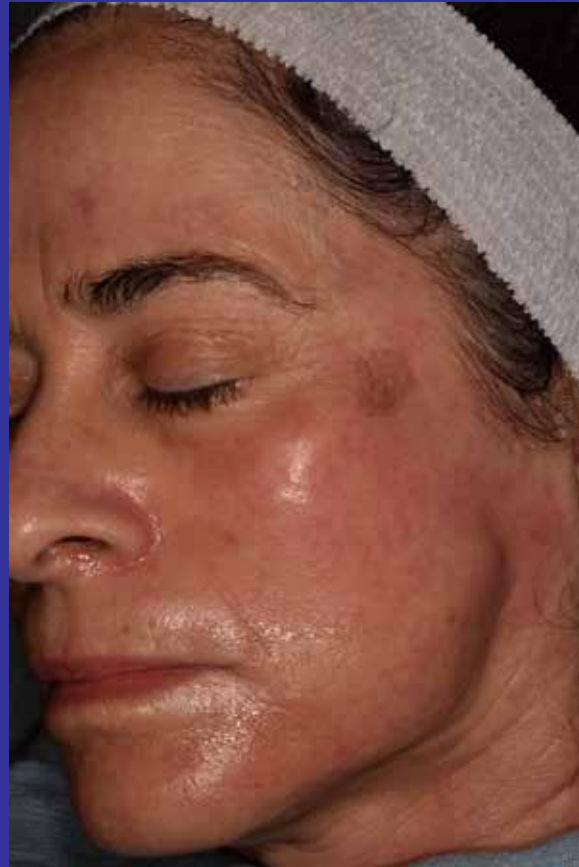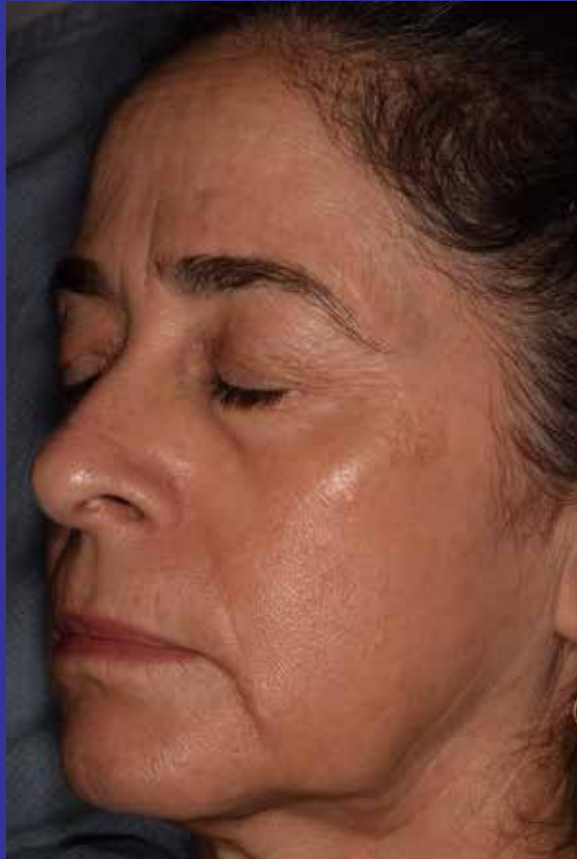Tough pigment patient



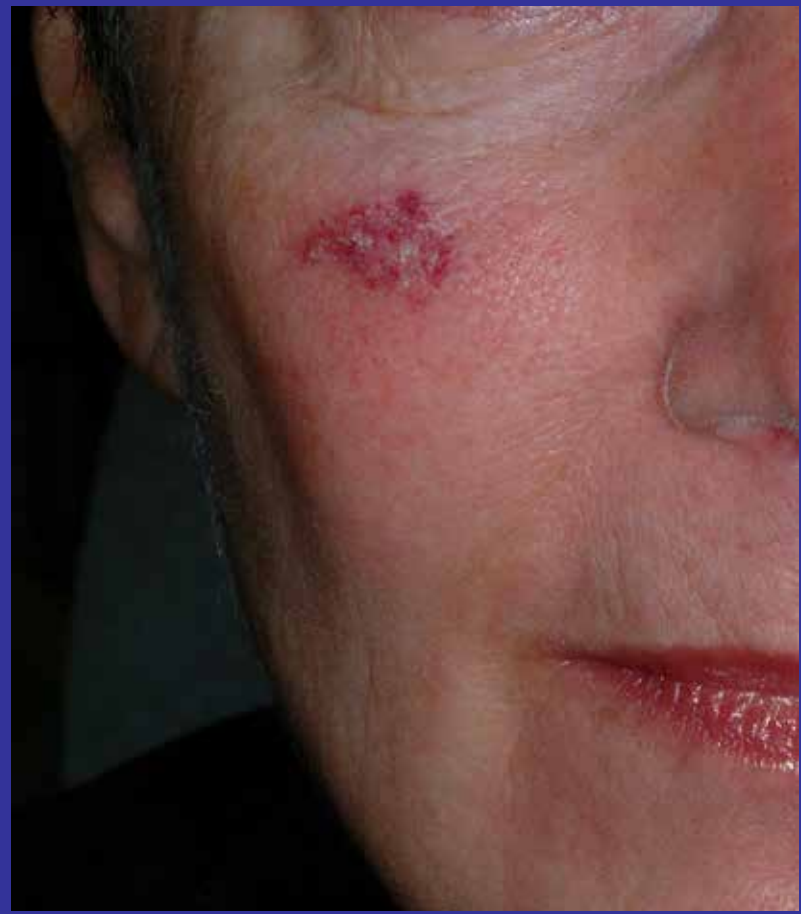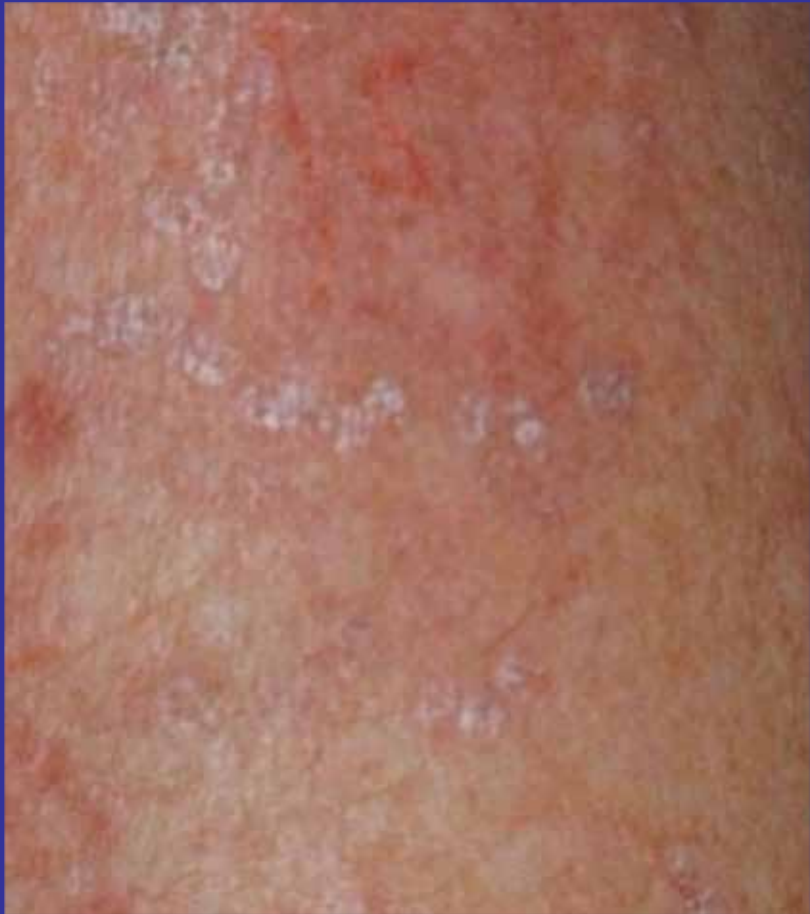How would you treat tough case



532 nm with compression



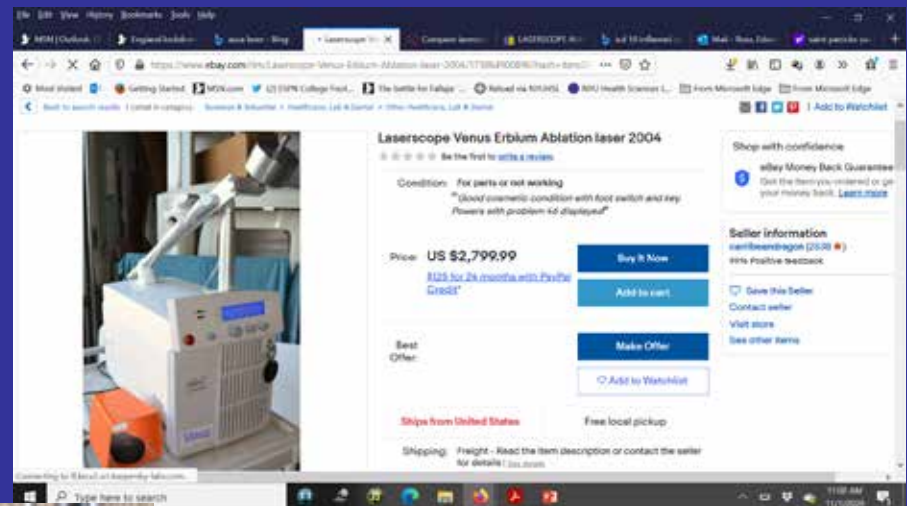
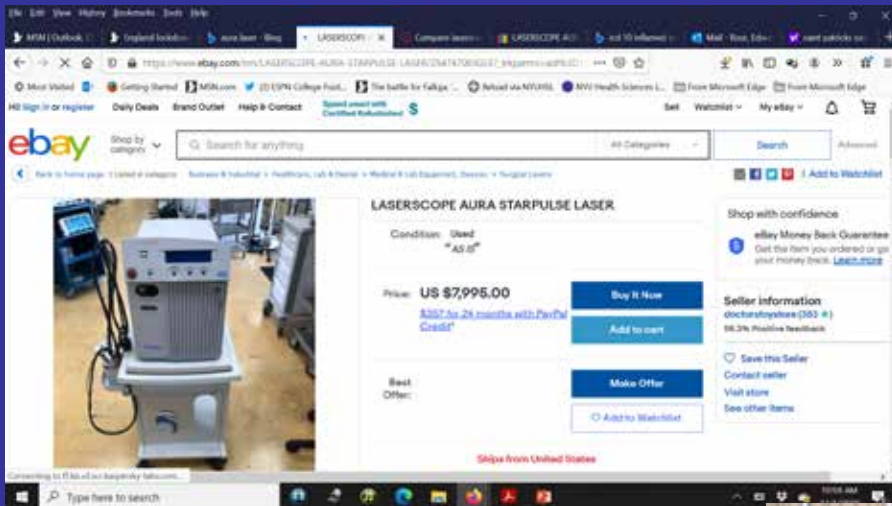
Alex-----532 nm



others

- Venus erbium laser
- Aura KTP

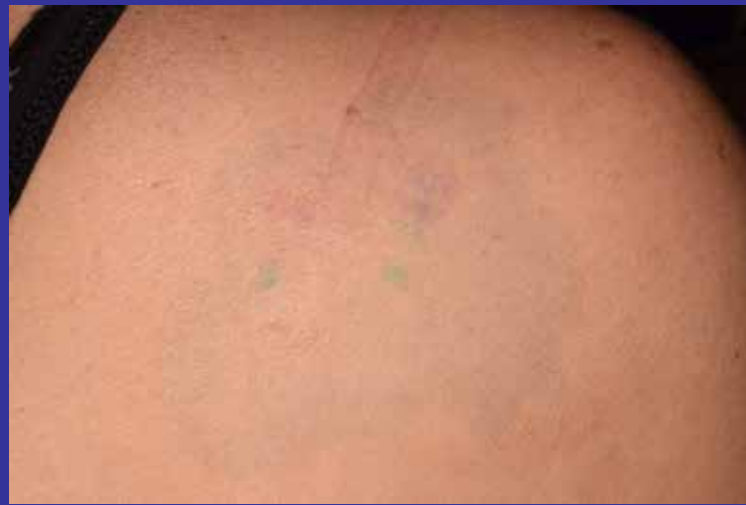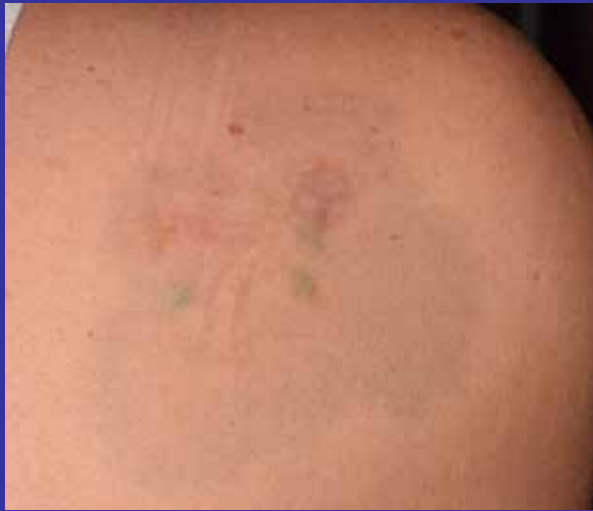Relegated to ebay! Please rescue!



Stand by me!!!!



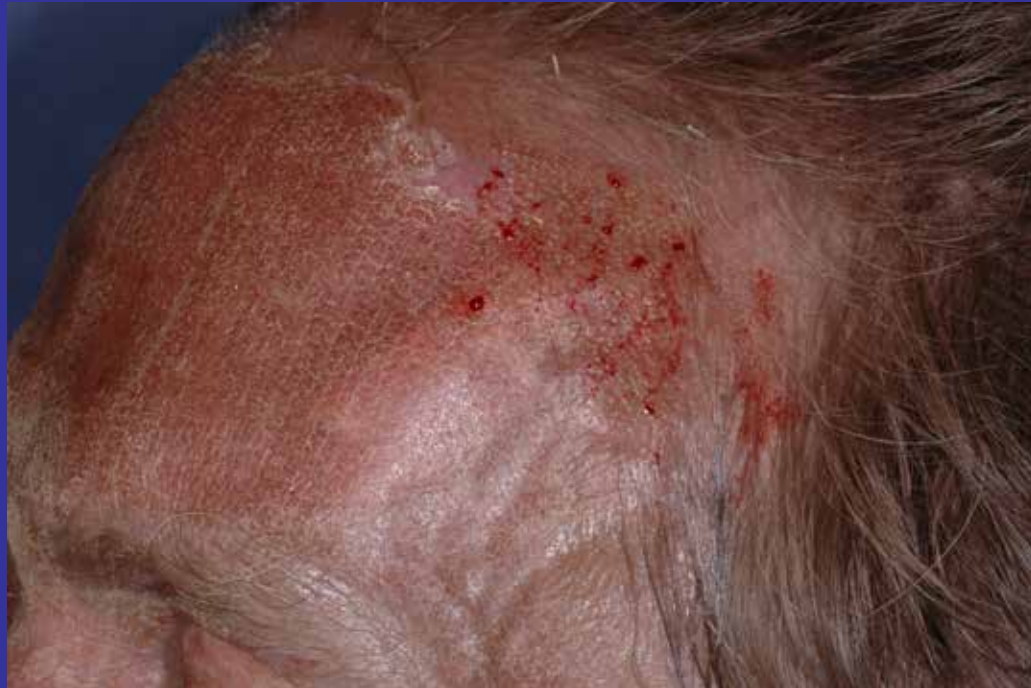Pre and post microneedle and long pulse alex fraxel



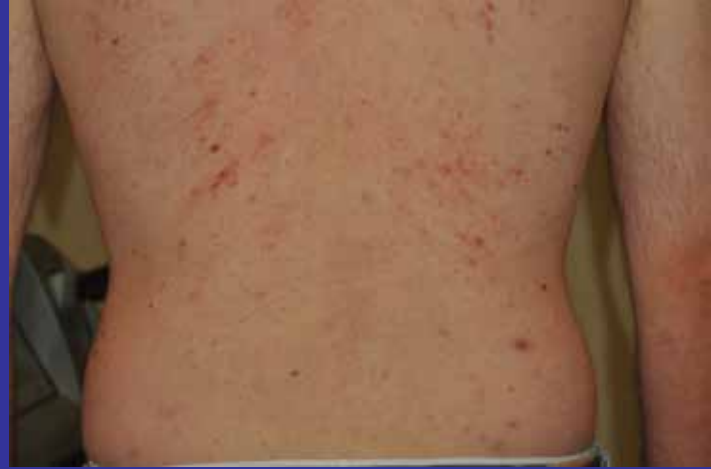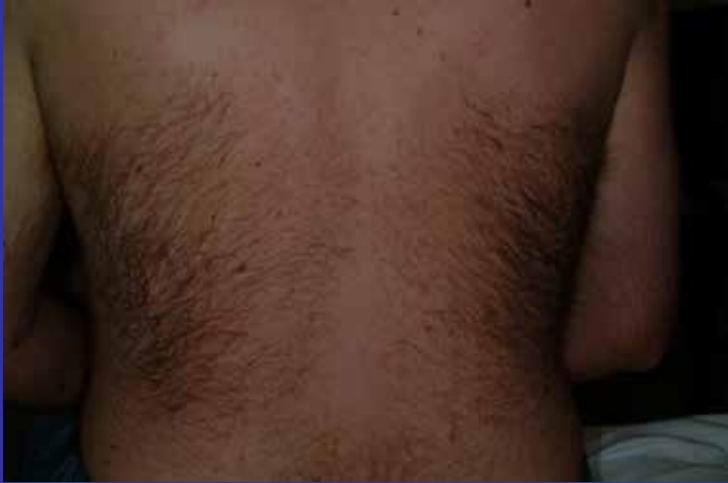argyria



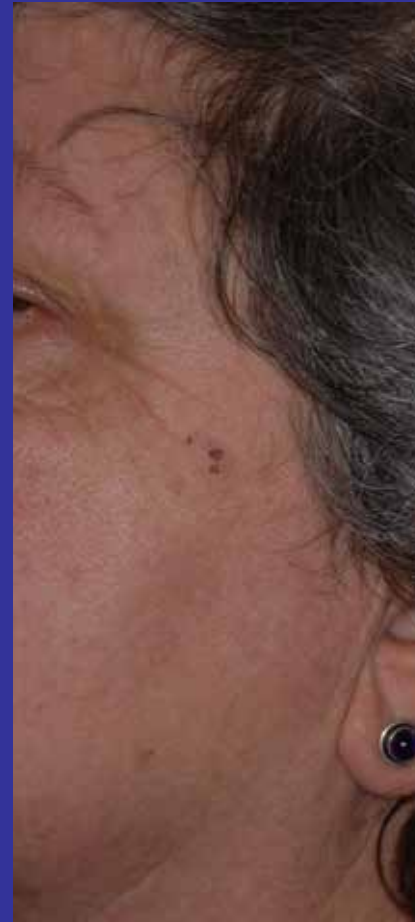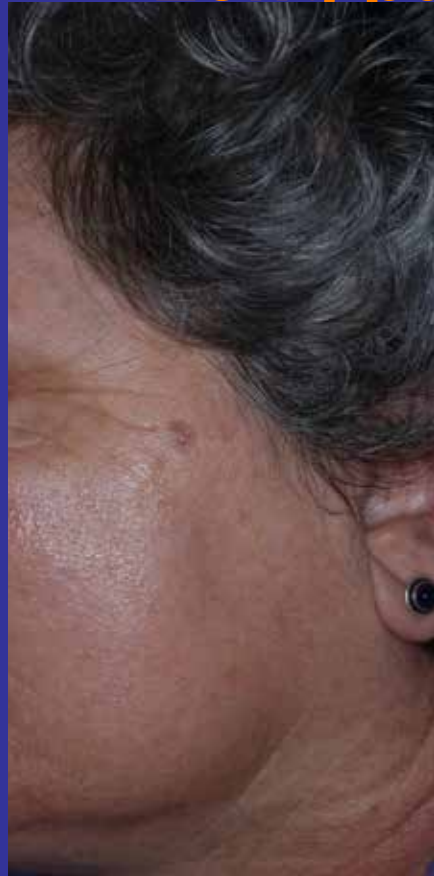Just post Profractional and standard peel



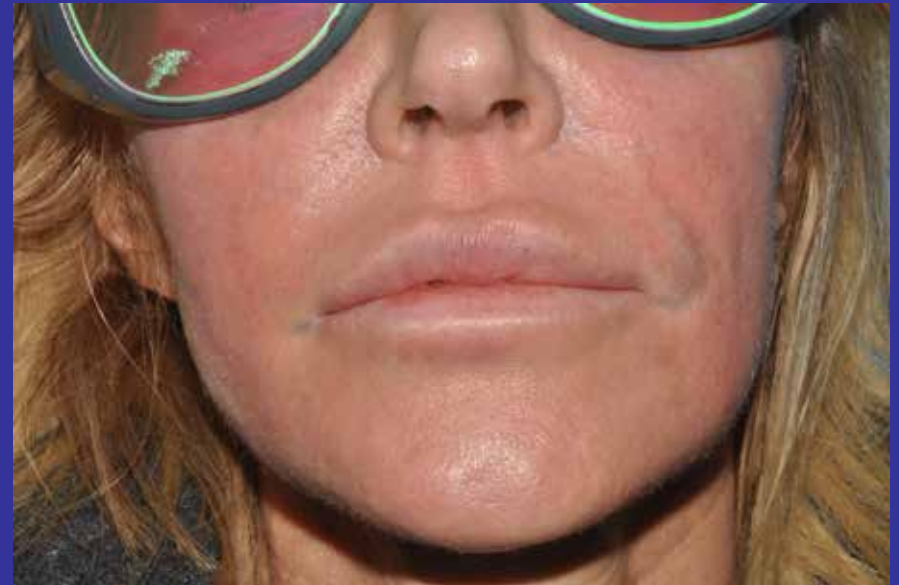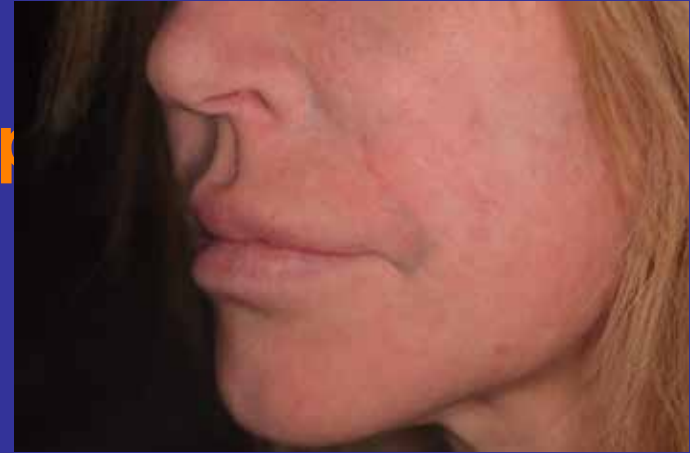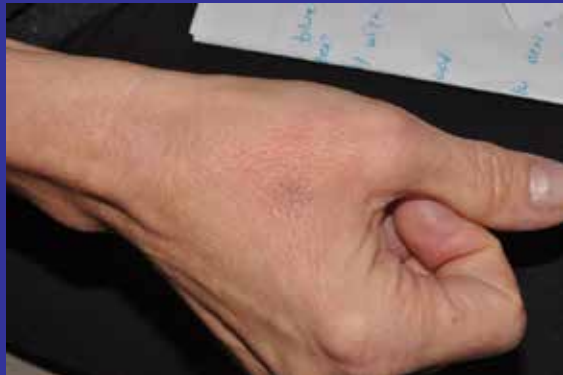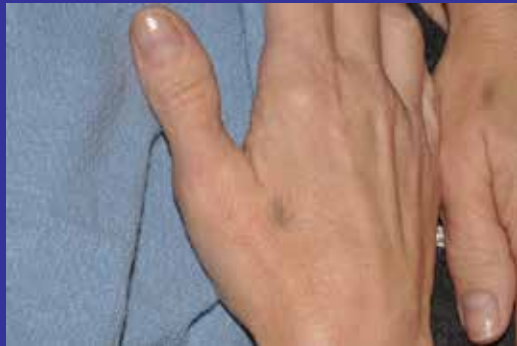Low fluence Diode



Long pulsed alex no cool



Minocin filler acup



Others

- Osteoam cutsis in dark skinned patient

